

COMPUTED TOMOGRAPHY-GUIDED BIOPSY OF PULMONARY LESIONS: DIAGNOSTIC YIELD AND COMPLICATION RATE

Ena Mršić¹, Ana Mršić¹, Eduard Oštarijaš¹, Melita Kukuljan^{1,2}

¹ University of Rijeka, Faculty of Medicine, Braće Branchetta 20/1, 51 000 Rijeka, Croatia

² Clinical Hospital Center Rijeka, Department of Radiology, Krešimirova ulica 42, 51 000 Rijeka, Croatia

Korespondenca/Correspondence: doc.dr.sc. Melita Kukuljan, dr. med., email: kukuljan.melita@gmail.com

Prejeto/Received: 23. 6. 2019

Sprejeto/Accepted: 31. 7. 2019

ABSTRACT

Aim: The purpose of this study is to assess the diagnostic accuracy of computed tomography-guided transthoracic biopsy (TTB), and to determine the type and incidence of complications.

Methods: This was a retrospective analysis of 124 CT-guided TTB of the pulmonary lesions at the Department of Radiology at the Rijeka Clinical Hospital Center. All patients were followed for 6-12 months after the biopsy to verify the accuracy of pathohistological diagnosis and were divided into four groups: true and false-positive and true and false-negative groups. The sensitivity, specificity, diagnostic accuracy, positive and negative predictive values were calculated.

Results: Out of the total number of biopsies, 71.8% of the procedures were performed on men and 28.2% on women. The largest group of patients (44.4%) were between the age of 66 and 75. Pneumothorax was reported in 27 procedures (21.8%), and pulmonary hemorrhage occurred in 9 biopsies (7.1%). No patient had any symptoms of complications, and no case required chest tube placement. The diagnostic accuracy, sensitivity, specificity, positive and negative predictive values were 97.6%, 97.4%, 100%, 100%, 75%, respectively.

Conclusion: CT-transthoracic needle biopsy is a gold standard for peripheral and paracentric lung lesions diagnostics. This study shows an acceptable rate of complications a the null rate of chest tube placement or severe complications. Also, we presented the diagnostic significance of this method in the two years at the Rijeka Clinical Hospital Center. As with any diagnostic procedures, further technological and technical development is vital.

Keywords: Image-Guided Biopsy; Pneumothorax; Radiology; Thorax

INTRODUCTION

Transthoracic needle biopsy (TTB) is a minimally invasive diagnostic method that is used to obtain a tissue sample for cytological and pathohistological analysis. Pulmonary lesions with suspected malignant etiology must be diagnosed as early as possible. Various diagnostic methods are available, depending on the size and location of the lesions. In most cases, central lesions are accessible to bronchoscopic sampling, while CT-guided TTB is recommended for the diagnosis of paracentral and peripheral lesions. The suitability of the aforementioned diagnostic method is a minimally invasive approach by which alternative diagnostic procedures, such as thoracoscopy or exploratory thoracotomy, are avoided.

Indications for TTB are pulmonary, mediastinal, and other thoracic solitary or multiple nodules or masses which, due to suspected malignant etiology, should be analyzed. Furthermore, it is often necessary to re-biopsy and re-evaluate pathohistological diagnosis after malignant progression. Indications for TTB are lesions with inflammatory characteristics that do not regress to therapy and hilar masses with unsuccessful or negative bronchoscopic biopsy results. (Anzidei et al., 2017; Bichard, 2011; Guo et al., 2018)

Contraindications for TTB are uncooperative patients, inability to control the cough or breathing on demand, and unsigned informed consent. Also, the biopsy is contraindicated if arterial venous malformation and hydatid cyst are suspected. Patients with unregulated coagulopathy, severe pulmonary hypertension, or chronic obstructive pulmonary disease also should not undergo biopsy. (Anzidei et al., 2017; Bichard, 2011) Minor complications of transthoracic biopsy are pneumothorax, pulmonary hemorrhage, and transient hemoptysis. Major complications include intervention requiring pneumothorax, hemothorax, air embolism, needle tract seeding, and death. The major complication rate is low in CT-guided lung biopsy. (Heerink et al., 2017)

This study aims to evaluate the diagnostic accuracy, sensitivity, specificity, the positive predictive value (PPV), and negative predictive value (NPV) of our biopsy technique and to determine the incidence of pneumothorax and pulmonary hemorrhage.

METHODS

In this retrospective study, we collected the data of 124 CT-guided TTB performed at the Department of Radiology at the Rijeka Clinical Hospital Center from January 2017 to January 2019. Uncooperative patients were excluded from the study because of the higher risk of additional complications. Prerequisites for TTB are a signed informed consent and valid coagulation test (not older than seven days). Also, patients are advised not to take anticoagulant therapy four days before the procedure. TTB was performed on 124 patients, 89 (71.8%) men and 35 (28.2%) women. The average age of men was 71, and the mean age of women was 66 years.

We explained the procedure, possible complications and the goals of the biopsy to each patient, as well as breathing instructions since compliance is essential. Every patient signed informed consent. We placed the patient in the most comfortable and convenient position for the procedure, and the patient remained entirely calm during the intervention.

All biopsies in our facility were performed by one radiologist with more than 15 years of experience. Chest CT scan was performed on each patient before the procedure, by which the exact depth and size of the lesion were determined.

Based on the chest CT scan, we positioned the patient and planned the safest access to the lesion to avoid damage to the larger blood vessels and bronchi. Once the needle entry point is determined, it is mandatory to disinfect the skin with alcohol. In all patients, the puncture site was subcutaneously injected with local anesthetic (2 ml of 2% lidocaine) immediately before the intervention. After the skin incision, all biopsies were performed with an 18-gauge or 16-gauge cutting needle. At least two scans are required for superficial lesions: one before pleural puncture and one before entering the lesion. Deeper lesions require at least three scans, first before penetrating the pleura, second about halfway to the lesion and third scan after entering the lesion. Additional scanning was required to check the needle position, in cases of missed puncture of the lesion by the radiologist and if patient's cooperation was inadequate. When the needle is inserted in the lesion, radiologist removes the tissue cylinder and withdraws the needle from the chest. Finally, the collected tissue sample is put in formalin and sent to pathohistological analysis, and its imprint for cytological analysis. The site of the biopsy should then be covered with sterile gauze. After the procedure, a control chest CT scan is performed to detect any complications.

Cytological and/or histological findings were assessed and divided into two diagnostic categories. The first category included the diagnosis of primary or secondary malignant tumours. Patients with any of these diagnoses were included in the group with positive findings. Positive pathohistological findings after surgery and the regression of the lesion after oncologic therapy confirmed the diagnosis. All positive cytologic and/or histological diagnoses were confirmed; therefore, all patients included in the group were true positives. There were no false-positives. The second diagnostic category included those patients diagnosed as having benign entities and those with negative histopathologic or cytopathologic results. In both cases, the patients were clinically monitored with controlled non-invasive radiological methods for 6-12 months. If during this period, findings regressed or remained the same, patients were determined to have a true-negative result. When the clinical course and CT findings indicated malignant lung disease, patients were determined to have a false-negative result. In this group of patients, the diagnosis was established by open surgical biopsy or repeated bronchoscopy.

The Ethics Committee of the Rijeka Clinical Hospital Center has approved the conduct of this research. Patient data were collected from a hospital information system (WIN BIS), while TTB information was gathered from the ISSA application. Diagnostic contribution of the method was determined by sensitivity, specificity, positive and negative predictive value and overall diagnostic accuracy test.

RESULTS

Between January 2017 and January 2019, 124 biopsies were performed, 71.8% on men and 28.2% on women. The youngest patient was 41, and the oldest was 87. Most patients (44.4%) were between the age of 66 and 75, 19.4% were younger than 65, and 36.3% were older than 75 years.

Of the total number of biopsies, 27 (21.8%) resulted in pneumothorax and 9 (7.1%) in pulmonary bleeding. The average pneumothorax width was 14,4mm. Pneumothorax occurred in 17 men (63%) and 10 women (37%) (Figure 1). We also presented the age distribution of patients with pneumothorax (Figure 2). Three patients with pneumothorax were hospitalized at the Department of Pulmonology, two of them for 24 hours, and one patient for four days, mostly because their place of residence was not well connected with other major centers. Those three patients were treated conservatively with an oxygen mask with a maximum flow rate of 15L/h. No patient had symptoms of pneumothorax, and no case required chest tube placement. The most common pathohistological and cytological finding among our subjects was adenocarcinoma with an incidence of 41.1%, followed by squamous cell carcinoma with an incidence of 25.8%. Non-small cell carcinoma, without detailed differentiation, was diagnosed in 7.3%, neuroendocrine carcinoma in 5.7%, and small cell carcinoma in 2.4% of all biopsies. In addition to the above, two mesothelioma (1.6%), two hemangiopericytomas (1.6%), one thymoma (0.8%), synovial sarcoma (0.8%), non-Hodgkin's lymphoma (0.8%)

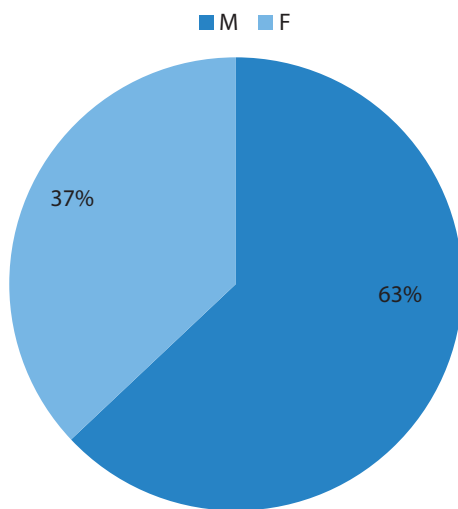


Figure 1: Gender distribution of patients with pneumothorax

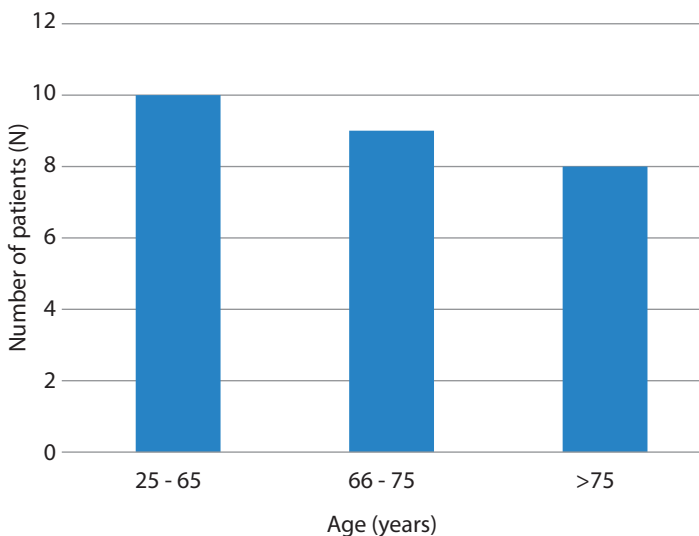


Figure 2: Age distribution of patients with pneumothorax

Table 1: Results of cytological and pathohistological analysis

Pathohistological and cytological diagnosis	N	Percentage (%)
Adenocarcinoma	51	41,1
Squamous cell carcinoma	32	25,8
Neuroendocrine carcinoma	7	5,7
Mesothelioma	2	1,6
Hemangiopericytoma	2	1,6
Thymoma	1	0,8
Synovial sarcoma	1	0,8
Non-Hodgkin's lymphoma	1	0,8
Leiomyosarcoma	1	0,8
Non-small cell carcinoma	9	7,3
Small cell carcinoma	3	2,4
Suggestive results	2	1,6
Negative results	12	9,7
Total	124	100

Table 2: Diagnostic significance

Diagnostic significance	N / %
True positive	112
True negative	9
False positive	0
False negative	3
Sensitivity (%)	97.4 (112/115)
Specificity (%)	100 (9/9)
Diagnostic accuracy (%)	97.6 (121/124)
Positive predictive value (%)	100 (112/112)
Negative predictive value (%)	75 (9/12)

and leiomyosarcoma (0.8%), along with two suggestive findings of malignant etiology (1.6%) were diagnosed (Table 1). Out of the total number of biopsies, 12 or 9.7% resulted in a negative histopathological and cytological diagnosis. Nine of the mentioned 12 were true negative, and three were false-negative results. Two patients, out of three false-negative results, were subjected to surgical biopsy, and the third to repeated bronchoscopy. In all three patients, alternative methods resulted in positive pathohistological results. All patients in our study were monitored for 6-12 months after the biopsy to verify the accuracy of the diagnosis. We divided the biopsy results into four groups: true positive (n = 112), false positive (n = 0), true negative (n = 9), and false negative (n = 3). Based on the obtained data, the diagnostic accuracy was 97.6%, sensitivity 97.4%, specificity and positive predictive value 100%, and negative predictive value 75% (Table 2).

DISCUSSION

We conducted this study to verify the diagnostic accuracy of our method and to determine the incidence of complications: pneumothorax and pulmonary bleeding. The ultimate aim of this research is to compare our results with the results of other recent studies.

Pulmonary bleeding in our study occurred in nine patients (7.1%) while most authors reported incidences of pulmonary bleeding higher than ours. The incidences in recent studies varies according to different reports, ranging 2.5-45.4% (Lee and Lee, (2016), Lazgouet et al. (2016), Tian et al. (2017), Yang et al. (2015), Wang et al. (2014), Görgülü et al. (2017), Khan et al. (2008), Li et al. (2013), Zhao et al. (2017), Li et al. (2017), Schulze et al. (2015), Wattanasatesiri et al. (2018), Aktaş et al. (2015a), Yun et al. (2018), Lu et al. (2012), Heyer et al. (2018), Aktas et al. (2015b)).

The pneumothorax rate in our study is 21.8% (27 biopsies). The incidence of pneumothorax during transthoracic needle biopsy varies according to different studies and ranges from 4.1 to 47.3%. The following authors reported incidence lower than 22%: Lee and Lee (2016), Lazgouet et al. (2016), Tian et al. (2017), Yang et al. (2015), Wang et al. (2014), Görgülü et al. (2017), Khan et al. (2008), Li et al. (2013), Zhao et al. (2017), Li et al. (2017), Schulze et al. (2015), Wang et al. (2016), Cruz et al. (2014). Rate of pneumothorax higher than 22% was reported by Wattanasatesiri et al. (2018), Aktaş et al (2015a), Yun et al. (2018), Lu et al. (2012), Heyer et al. (2008), Aktas et al. (2015b), Fontaine-Delaurelle et al. (2017), Brandén et al. (2014) and Kuban et al. (2015). The pneumothorax rate in our study is comparable to the rates reported in recent literature.

In our study, no patient with pneumothorax required chest tube placement. To our knowledge, only a few authors reported a zero per cent rate of chest tube placement: Lazgouet et al. (2016), Görgülü et al. (2017), Lu et al. (2012) and Zhao et al. (2017). Most authors reported an incidence of chest tube placement in a range from 1 to 10%: Yang et al. (2015), Wang et al. (2014), Li et al. (2013), Khan et al. (2008), Wattanasatesiri et al. (2018), Heyer et al. (2008), Schulze et al. (2015), Li et al. (2017). Branden et al. (2014), Cruz et al. (2014), Fontaine-Delaruelle et al. (2017), Hiraki et al. (2010), Yun et al. (2018). In contrast, Kuban et al. (2015) presented the incidence of chest tube placement in 15% of performed biopsies and reported that a 19-gauge coaxial guide needle significantly decreases the risk of pneumothorax and chest tube placement compared with an 18-gauge needle.

Major complications, such as hemothorax, pulmonary embolism or fatal outcome, have not occurred in our study. Tian et al. (2017), Fontaine-Delaruelle et al. (2017) and Wang et al. (2014) reported the incidence of hemothorax to be lower than 2%, while Aktas et al. (2015a) and Aktas et al. (2015a) reported an incidence of 4%. Three authors reported a fatal outcome: Fontaine-Delaruelle et al. (2017), Ocağ et al. (2016) and Padrão et al. (2018). The following authors reported the cases of pulmonary embolism: lalongo et al. (2017), Pando et al. (2015), Hung et al. (2015), Smit et al. (2013), Kukuljan et al. (2018) and Galvis et al. (2017).

The diagnostic contribution of transthoracic biopsy in our study (sensitivity 97.4%, specificity 100%, diagnostic accuracy 97.6%, positive predictive value 100%, and negative predictive value 75%) is comparable with reports by Yang et al. (2015) (95.3%, 95.7%, 92.9%, 99.2% and 78.6%), Wang et al. (2014) (97.3%, 100%, 97.7%, 100% and 87.7%) and Yun et al. (2018) (83%, 99%, 87.6%, 99.5% and 69.9%). The NPV in our study was 75% due to three necrotic samples, which were classified as false-negative findings. Tian et al. (2017) reported the diagnostic contribution of the transthoracic biopsy of lesions smaller than 30 mm. The overall sensitivity,

specificity, accuracy, PPV and NPV for diagnosis of malignancy were 92%, 98.6%, 94.6%, 100%, and 90.9% respectively. Li et al. (2013) showed the results of CT-guided percutaneous core needle biopsy for lesions smaller than 20 mm. The overall diagnostic accuracy was 93.5%, the sensitivity for malignancy and specificity for benign lesions were 90.4% and 100%, while positive and negative predictive values were 100% and 83.3%, respectively.

Finally, a comparison of our results with the results of recent studies showed a comparable pneumothorax incidence and comparable diagnostic accuracy. The significant difference between our study and most recent studies was the 0% rate of chest tube placement. We assume that this is a great benefit because pneumothorax is not a significant clinical problem if chest tube placement is not needed.

CONCLUSION

We conducted this study on 124 transthoracic biopsies of pulmonary lesions performed at the Department of Radiology at the Rijeka Clinical hospital Center from January 2017 to January 2019. The results of this study directly show the success of this procedure. Diagnostic accuracy is 97.6%, sensitivity 97.4%, specificity and positive predictive value is 100%, and negative predictive value is 75%. The incidence of pneumothorax was 21.8%, and the rate of pulmonary bleeding was 7.1%. No patient had symptoms of the mentioned complications, and this diagnostic procedure can be labeled as safe due to the low rate of severe complications. (Heerink et al., 2017)

CT-guided TTB is an excellent diagnostic method for peripheral and paracentral pulmonary lesions. Furthermore, TTB is a relatively fast procedure that does not require general anesthesia. The patient is aware and can cooperate with the radiologist, which is one of the essential characteristics of this intervention. In the case of unsuccessful biopsies, we recommend repeating the biopsy, given the very high overall diagnostic accuracy and low complication rate.

LITERATURE

Aktaş AR, Gözlek E, Yılmaz Ö et al. (2015a) CT-guided transthoracic biopsy: histopathologic results and complication rates. *Diagnostic and Interventional Radiology* 21(1): 67–70.

Aktas AR, Gozlek E, Yazkan R et al. (2015b). Transthoracic biopsy of lung masses: Non technical factors affecting complication occurrence. *Thoracic Cancer* 6(2): 151–8.

Anzidei M, Porfiri A, Andrani F et al. (2017). Imaging-guided chest biopsies: techniques and clinical results. *Insights into Imaging* 8(4): 419–428.

Bichard KR (2011). Transthoracic Needle Biopsy. *Seminars in Interventional Radiology* 28(1): 87–97.

Cruz JF, Rolo R, Iglésias L, Cunha J (2014). CT-guided transthoracic lung biopsy: Predictive factors of pneumothorax. *Revista Portuguesa de Pneumologia* 20(3): 174–6.

- Fontaine-Delaruelle C, Souquet PJ, Gamondes D et al. (2017). Facteurs prédictifs de complications des ponctions transpariétales thoraciques. *Revue de Pneumologie Clinique* 73(2): 61–67.
- Galvis JM, Nunley DR, Zheyi T, Dinglasan LAV (2017). Left ventricle and systemic air embolism after percutaneous lung biopsy. *Respiratory medicine case reports* 22: 206-208.
- Görgülü FF, Öksüzler FY, Arslan SA, Arslan M, Özsoy IE, Görgülü O (2017). Computed tomography-guided transthoracic biopsy: Factors influencing diagnostic and complication rates. *Journal of International Medical Research* 45(2): 808–815.
- Guo Z, Shi H, Li W et al. (2018). Chinese multidisciplinary expert consensus: Guidelines on percutaneous transthoracic needle biopsy. *Thoracic cancer* 9(11): 1530-1543.
- Heerink WJ, de Bock GH, de Jonge GJ, Groen HJ, Vliegenthart R, Oudkerk M (2017). Complication rates of CT-guided transthoracic lung biopsy: meta-analysis. *European radiology* 27(1):138-148.
- Heyer CM, Reichelt S, Peters SA, Walther JW, Müller KM, Nicolas V. (2008). Computed Tomography–Navigated Transthoracic Core Biopsy of Pulmonary Lesions. *Academic Radiology* 15(8): 1017–26.
- Hiraki T, Mimura H, Gobara H et al. (2010). Incidence of and Risk Factors for Pneumothorax and Chest Tube Placement After CT Fluoroscopy–Guided Percutaneous Lung Biopsy: Retrospective Analysis of the Procedures Conducted Over a 9-Year Period. *American Journal of Roentgenology* 194(3): 809–14.
- Hung WH, Chang CC, Ho SY, Liao CY, Wang BY (2015). Systemic air embolism causing acute stroke and myocardial infarction after percutaneous transthoracic lung biopsy—a case report. *Journal of cardiothoracic surgery* 10: 121.
- Ialongo P, Ciarpaglini L, Tinti MD, Suadoni MN, Cardillo G (2017). Systemic air embolism as a complication of percutaneous computed tomography guided transthoracic lung biopsy. *Annals of the Royal College of Surgeons of England* 99(6): e174-e176.
- Khan MF, Straub R, Moghaddam SR et al. (2008). Variables affecting the risk of pneumothorax and intrapulmonary hemorrhage in CT-guided transthoracic biopsy. *European Radiology* 18(7): 1356–63.
- Kuban JD, Tam AL, Huang SY et al. (2015). The Effect of Needle Gauge on the Risk of Pneumothorax and Chest Tube Placement After Percutaneous Computed Tomographic (CT)-Guided Lung Biopsy. *CardioVascular and Interventional Radiology* 38(6): 1595–602.
- Kukuljan M, Kolić Z, Vukas D, Bonifačić D, Vrbanec K (2018). Nonfatal Systemic Air Embolism: A Grave Complication of Computed Tomography-Guided Percutaneous Transthoracic Needle Biopsy. *The Eurasian journal of medicine* 50(1): 44-46.
- Lazgouet Y, Maarouf R, Karriu M, Skiker I, Alloubi I (2016). CT guided percutaneous needle biopsy of the chest: initial experience. *The Pan African Medical Journal* 23: 211.
- Lee HY, Lee IJ (2016). Assessment of Independent Risk Factors of Developing Pneumothorax During Percutaneous Core Needle Lung Biopsy: Focus on Lesion Depth. *Iranian Journal of Radiology* 13(4): e30929.
- Li GC, Fu YF, Cao W, Shi YB, Wang T (2017). Computed tomography-guided percutaneous cutting needle biopsy for small (≤ 20 mm) lung nodules. *Medicine* 96(46): e8703.
- Li Y, Du Y, Yang HF, Yu JH, Xu XX (2013). CT-guided percutaneous core needle biopsy for small (≤ 20 mm) pulmonary lesions. *Clinical Radiology* 68(1): e43–e8.
- Lu CH, Hsiao CH, Chang YC et al. (2012). Percutaneous Computed Tomography-Guided Coaxial Core Biopsy for Small Pulmonary Lesions with Ground-Glass Attenuation. *Journal of Thoracic Oncology* 7(1): 143–50.
- Ocak S, Duplaquet F, Jamart J et al. (2016). Diagnostic Accuracy and Safety of CT-Guided Percutaneous Transthoracic Needle Biopsies: 14-Gauge versus 22-Gauge Needles. *Journal of Vascular and Interventional Radiology* 27(5): 674–81.
- Padrão E, Rodrigues M, Guimarães S et al. (2018). Diagnostic Yield of Computed Tomography-Guided Transthoracic Lung Biopsy in Diffuse Lung Diseases. *Respiration* 96(5): 455-463.
- Pando Sandoval A, Ariza Prota MA, García Clemente M, Prieto A, Fole Vázquez D, Casán P (2015). Air embolism: a complication of computed tomography-guided transthoracic needle biopsy. *Respirology Case Reports* 3(2): 48–50.
- Schulze R, Seebacher G, Enderes B, Kugler G, Fischer JR, Graeter TP (2015). Complications in CT-Guided, Semi-Automatic Coaxial Core Biopsy of Potentially Malignant Pulmonary Lesions. *RöFo - Fortschritte Auf Dem Gebiet Der Röntgenstrahlen Und Der Bildgebenden Verfahren* 187(08): 697–702.
- Smit DR, Kleijn SA, de Voogt WG (2013). Coronary and cerebral air embolism: a rare complication of computed tomography-guided transthoracic lung biopsy. *Netherlands Heart Journal* 21(10): 464-6.
- Tian P, Wang Y, Li L, Zhou Y, Lou W, Li W (2017). CT-guided transthoracic core needle biopsy for small pulmonary lesions: diagnostic performance and adequacy for molecular testing. *Journal of Thoracic Disease* 9(2): 333–343.
- Wang Y, Jiang F, Tan X, Tian P (2016). CT-guided percutaneous transthoracic needle biopsy for paramediastinal and nonparamediastinal lung lesions. *Medicine* 95(31): e4460.
- Wang Y, Li W, He X, Li G, Xu L (2014). Computed tomography-guided core needle biopsy of lung lesions: Diagnostic yield and correlation between factors and complications. *Oncology letters* 7(1): 288–294.

Wattanasatesiri T, Puntu W, Vithitsuvanakul N (2018). Influencing factors of pneumothorax and parenchymal haemorrhage after CT-guided transthoracic needle biopsy: single-institution experience. *Polish journal of radiology* 83: e379-e388.

Yang W, Sun W, Li Q, et al. (2015). Diagnostic Accuracy of CT-Guided Transthoracic Needle Biopsy for Solitary Pulmonary Nodules. *PLoS One* 10(6): e0131373.

Yun S, Kang H, Park S, Kim BS, Park JG, Jung MJ (2018). Diagnostic accuracy and complications of CT-guided core needle lung biopsy of solid and part-solid lesions. *The British Journal of Radiology* 91(1088):20170946.

Zhao G, Shi X, Sun W et al. (2017). Factors affecting the accuracy and safety of computed tomography-guided biopsy of intrapulmonary solitary nodules ≤ 30 mm in a retrospective study of 155 patients. *Experimental and Therapeutic Medicine* 13(5): 1986–92.