

Review article

MAGNETIC RESONANCE IMAGING IN THE ASSESSMENT OF FETAL CENTRAL NERVOUS SYSTEM ANOMALIES

Edina SALKIĆ¹, Fuad JULARDŽIJA^{2,3*}, Adnan ŠEHIĆ^{2,3}, Merim JUSUFBEGOVIĆ^{2,4}, Amela SOFIĆ⁵, Meris JUŠIĆ⁶, Jasmina BAJROVIĆ^{2,4}

¹ MSc student, Faculty of Health Studies, University of Sarajevo, Sarajevo, Bosnia and Herzegovina

² Department of radiology technologies, Faculty of Health Studies, University of Sarajevo, Sarajevo, Bosnia and Herzegovina

³ Institute for health development, Faculty of Health Studies, University of Sarajevo, Sarajevo, Bosnia and Herzegovina

⁴ Radiology clinic, Clinical center of Sarajevo University, Sarajevo, Bosnia and Herzegovina

⁵ Radiology department, General hospital "Prim. dr Abdulah Hakaš", Sarajevo, Bosnia and Herzegovina

⁶ PhD student, Faculty of Health Studies, University of Sarajevo, Sarajevo, Bosnia and Herzegovina

* Corresponding author: Fuad Julardžija, Department of radiology technologies, Faculty of Health Studies, University of Sarajevo, Stjepana Tomića 1, 71000 Sarajevo, Bosnia and Herzegovina e-mail: fuad.julardzija@fzs.unsa.ba

Received: 22. 11. 2021

Accepted: 11. 1. 2022

<https://doi.org/10.47724/MIRTJ.2021.i02.a001>

ABSTRACT

Introduction: Fetal central nervous system (CNS) anomalies are among the most severe and common anomalies, with an incidence of 1:100 to 1:500 in newborns. Depending on the type of anomaly, the diagnosis can only be made at specific periods of pregnancy. The prenatal ultrasound (US) is an effective primary imaging modality for depicting these anomalies, and magnetic resonance imaging (MRI) is a method that provides useful confirmation and resolves any doubts regarding the diagnosis made on prenatal ultrasound. In situations where ultrasound examination is difficult, fetal MRI can provide superior information owing to its many advantages. The aim of this study was to determine the importance of prenatal MRI in making an accurate diagnosis and assessment of fetal CNS anomalies after neurosonographic doubt and in detecting additional anomalies that might have been overlooked on ultrasound, which influences clinical decision making and anomaly outcomes.

Material and methods: For this research, which was designed as a systematic review of the primary scientific research literature, numerous articles were used, i.e. 17 scientific research papers, published in relevant scientific research online databases such as PubMed, Medline, Google Scholar, and the same were published in English in the period from 2015 to 2021.

Results: From the assessment of the quality of studies with a cohort design, most studies used in this systematic review are high-quality studies (11 in total) and a smaller number are medium-quality studies (6 in total). Out of 575 cases, MRI confirmed the ultrasound diagnosis and agreed with it in 59.8% of cases, while in 20.2% of cases, it changed the diagnosis, i.e., in 16.5%, it rejected the ultrasound diagnosis. Additional anomalies detected only on MRI occurred in 236/1225 cases, which totals 19.3% of additional anomalies. Termination of pregnancy was reported in 82/317 cases, accounting for 25.9%, while in 176 cases, the pregnancy continued. A total of 11 cases of neonatal death were reported, and the number of stillbirths or deaths after birth was reported in 8 cases.

Conclusion: MRI using T2W SSFSE sequences in 3 planes, T1W and DWI in the axial plane, is a complementary modality to prenatal ultrasound in making an accurate diagnosis and assessment of CNS anomalies and detecting associated anomalies previously overlooked on ultrasound.

Keywords: fetal magnetic resonance imaging, fetal neurosonography, fetal central nervous system anomalies, prenatal diagnosis.

INTRODUCTION

Magnetic Resonance Imaging (MRI) of the fetus or prenatal MRI is a non-invasive imaging method that shows the anatomical structures of the fetus without using ionizing radiation (1). Due to a higher contrast resolution than ultrasound, fetal MRI allows better differentiation of normal and abnormal tissue, thus providing detailed imaging data on fetal structures, especially the brain (2). MRI of the fetus is not recommended in the first trimester of pregnancy unless the fetus is life-threatening. The use of intravenous contrast agents is not recommended to reduce the potentially harmful effects on the fetus (3). The key function of fetal MRI is early detection of congenital anomalies incompatible with life that require termination of pregnancy or the detection of those anomalies that will undergo surgery (1). Although fetal ultrasound (US) is the first and basic screening method and an effective primary imaging modality for a depiction of central nervous system (CNS) abnormalities, MRI is a recognized complementary method for identifying fetal CNS pathology. It can provide additional and diagnostically important information, thus adding security to ultrasound diagnosis and assisting in parent counseling (4,5). The CNS anomalies are among themselves the most severe and common anomalies, with an incidence of 1: 100 to 1: 500 in newborns (6). Depending on the type of anomaly, the diagnosis can only be made at certain periods of pregnancy. Half of the anomalies are such that they lead either to the death of the fetus or significantly disrupt life after birth, which is why timely detection and treatment are of great importance (7). In situations where ultrasound examination is difficult, fetal MRI can provide superior information, owing to its advantages such as superior contrast resolution, increased visual field, the ability to shoot smoothly due to ossified skull, increased amounts of adipose tissue on the front abdominal wall, oligohydramnios, fetal bones, a small amount of amniotic fluid, the movements themselves, and an unfavorable position of the fetus are cases where MRI is a method of choice (8,9,10). In addition, a complete examination of the fetal CNS in the three spatial planes is obtained more consistently in the second and third trimesters by MRI than by ultrasound only (11). Prenatal fetal imaging has several challenges that require sequences that can minimize the effects of fetal movement and maternal breathing. The quality and resolution of the image should be such that they can adequately display essentially small anatomical details, and the differences in low tissue contrast should be made as large as possible to adequately define the brain parenchyma (12). The development of a fast retrieval sequence from a single image with refocused echo (T2 weighted) has revolutionized fetal MRI because it has a layer acquisition time of less than a second and allows for effective "freezing" of fetal movements (13). Typically, the fetal CNS assessment protocol includes T2 weighted images following three planes of the fetal head, axial and coronal T1 weighted images, axial diffusion images (DWI), and/or diffusion tensor images (DTI); and additional sequences are performed as needed (9). The aim of this study was to determine the importance of prenatal MRI in making an accurate diagnosis and assessment of fetal CNS anomalies after neurosonographic suspicion and in detecting additional anomalies missed on ultrasound, which influences clinical decision-making and anomaly outcomes.

MATERIAL AND METHODS

Numerous articles were used for this research, designed as a systematic review of the primary scientific research literature. There were 17 scientific research papers published in relevant scientific research online databases such as PubMed, Medline, Google Scholar, and the same were published in English. Based on them, an analysis was conducted, and the basic characteristics of the study were selected (country, author, year of publication, title, type, study objectives, research method, results, and study conclusion). The studies used in this paper were published from 2015 to 2021. Based on them, we compared the results of the two modalities (ultrasound and magnetic resonance). We tried to determine the advantage of magnetic resonance imaging in the accurate assessment of CNS anomalies and the detection of associated anomalies and their impact on decisions about further pregnancy. The criterion for inclusion in the study included those studies that included pregnant women who were diagnosed or suspected of certain CNS abnormalities on prenatal ultrasound diagnosis of the fetus and who were then subjected to magnetic resonance imaging. At the same time, the exclusion criterion included the omission of any inclusion criterion, studies published in the period before 2015, then studies involving other abnormalities outside the CNS, and cases with contraindications for performing magnetic resonance imaging, such as claustrophobia, implanted pacemakers, prostheses, etc. The Preferred Reporting Items for Systematic Reviews and Meta-Analyses (PRISMA) flow diagram was used to document and report on all decisions made during the study selection process for this review paper, including the initial number of identified studies, the number of excluded and included studies, and the reasons for their exclusion from the research (Diagram 1).

The search keywords were: fetal magnetic resonance imaging, fetal neurosonography, central nervous system anomalies, prenatal diagnosis

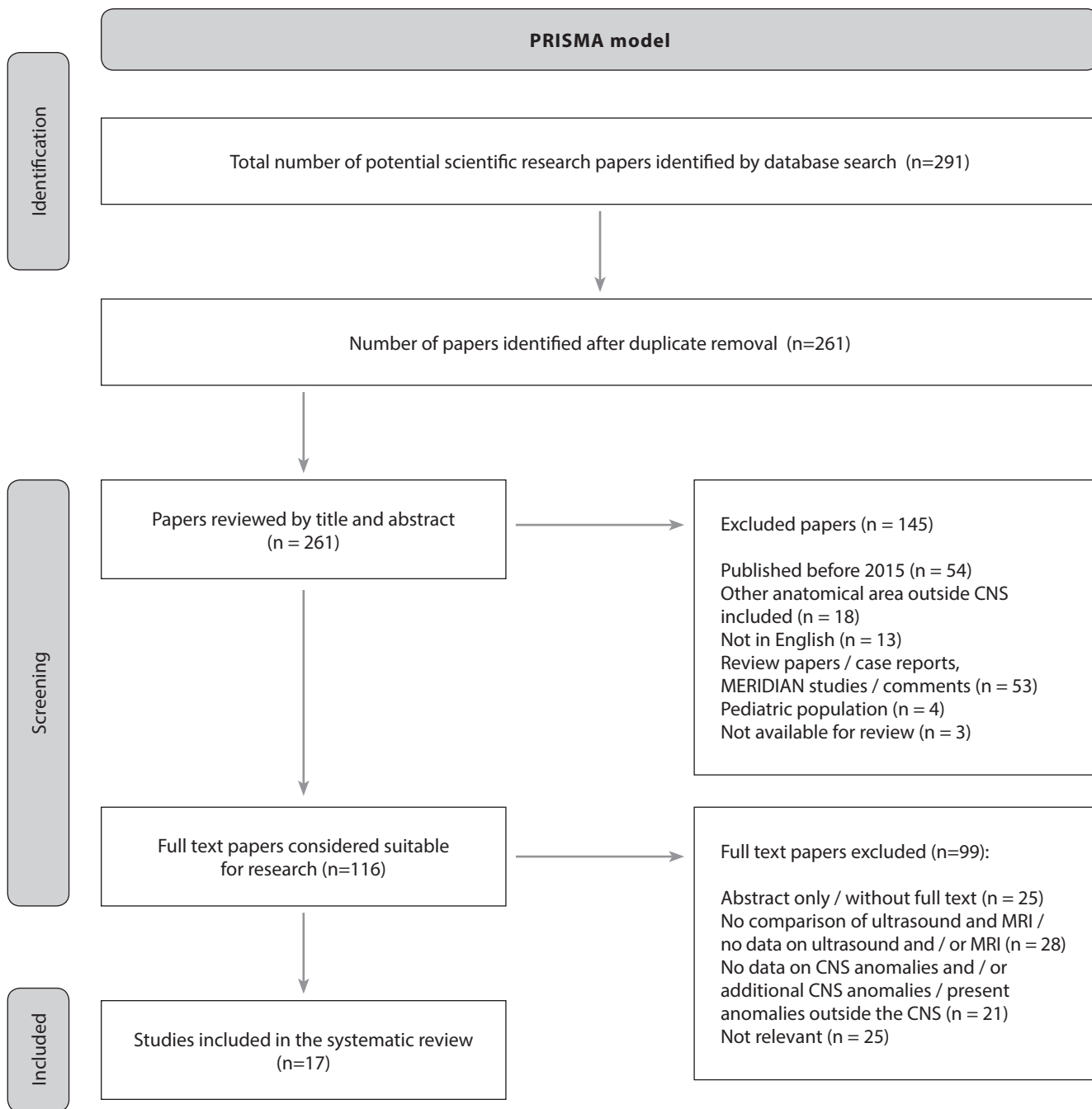


Diagram 1. PRISMA model

RESULTS

The quality assessment of the included cohort design studies (Table 1) was made according to the quality assessment tools developed by the National Heart, Lung and Blood Institute (NHLBI) in 2013 (14).

Studies in which all or nearly all criteria are met and the weaknesses of the study cannot change, the study's findings are qualified as *high-quality studies*. Furthermore, *medium-*

quality studies are considered to be those studies in which some of the criteria from the checklist are not met or if the criteria are not satisfactorily described. However, it is assumed that there is little chance that the weaknesses could have changed the study's findings. In addition, there are *inadequate/low-quality studies* that include those studies that meet several or no criteria from the checklist and in such studies, weaknesses may mean that the conclusion of the study is wrong (14)

Table 1. Quality assessment of included studies with a cohort design

Main author, year, country, title	1	2	3	4	5	6	7	8	9	10	11	12	Total assessment quality
The ENSO Working Group, 2020, Italy, Role of prenatal magnetic resonance imaging in fetuses with isolated mild or moderate ventriculomegaly in the era of neurosonography: an international multicenter study	Y	Y	Y	Y	Y	Y	N	Y	Y	Y	N	Y	Medium quality
Tanacan A. et al., 2020, Turkey, Prenatal diagnosis of central nervous system abnormalities: Neurosonography versus fetal magnetic resonance imaging	Y	Y	Y	Y	Y	Y	U	Y	Y	Y	Y	Y	High quality
Sefidbakht S. et al., 2016, Iran, Fetal Central Nervous System Anomalies Detected by Magnetic Resonance Imaging: A Two-Year Experience	Y	Y	Y	Y	N	Y	U	Y	Y	Y	Y	Y	Medium quality
Mazor MM. et al., 2018, Israel, Added Value of Fetal MRI in the Evaluation of Fetal Anomalies of the Corpus Callosum: A Retrospective Analysis of 78 Cases	Y	Y	Y	Y	Y	Y	N	Y	Y	Y	Y	Y	High quality
Raafat RME. et al., 2020, Egypt, The prevalence and the adding value of fetal MRI imaging in midline cerebral anomalies	Y	Y	Y	Y	Y	Y	Y	Y	Y	Y	Y	Y	High quality
Turkyilmaz G. et al., 2019, Turkey, Utilization of neurosonography for evaluation of the corpus callosum malformations in the era of fetal magnetic resonance imaging	Y	Y	Y	Y	Y	Y	U	Y	Y	Y	Y	Y	High quality
Irwin K. et al., 2016, Australia, Utility of fetal MRI for workup of fetal central nervous system anomalies in an Australian maternal-fetal medicine cohort	Y	Y	Y	Y	U	Y	U	Y	Y	Y	Y	Y	High quality
Linh LT. et al., 2021, Vietnam, Detecting Fetal Central Nervous System Anomalies Using Magnetic Resonance Imaging and Ultrasound	Y	Y	Y	U	Y	N	N	Y	Y	Y	Y	Y	Medium quality
Raafat M. et al., 2021, Egypt, Fetal brain MRI: how it added to ultrasound diagnosis of fetal CNS anomalies-1 year experience	Y	Y	Y	Y	Y	Y	U	Y	Y	Y	Y	Y	High quality
Jarre A. et al., 2017, Spain, Value of brain MRI when sonography raises suspicion of agenesis of the corpus callosum in fetuses	Y	Y	Y	Y	Y	Y	N	Y	Y	Y	Y	Y	High quality
Kandula T. et al., 2015, Australia, Isolated ventriculomegaly on prenatal ultrasound: what does fetal MRI add?	Y	Y	Y	Y	Y	Y	N	Y	Y	Y	Y	Y	High quality
Mahmod M. et al., 2021, Egypt, The impact of adding fetal MRI to sonographically diagnosed intrauterine ventriculomegaly: a prospective cohort study	Y	Y	Y	U	Y	U	U	Y	Y	Y	Y	Y	Medium quality
Yilmaz E. et al., 2018, Turkey, Additional Findings from Fetal Magnetic Resonance Imaging for Prenatal Sonographic Diagnosis of Central Nervous System Abnormalities	Y	Y	Y	Y	Y	Y	U	Y	Y	Y	Y	Y	High quality
Ziaulhaq P. et al. 2020, India, The comparative study of antenatal magnetic resonance imaging and ultrasound in the evaluation of fetal central nervous system abnormalities	Y	Y	Y	Y	N	U	N	Y	Y	Y	Y	Y	Medium quality
Velipaşaoğlu M. et al. 2018, Turkey, Assessment of the Additional Value of Fetal Magnetic Resonance Imaging to Prenatal Ultrasound in a Single Institution	Y	Y	Y	Y	N	U	N	Y	Y	Y	Y	Y	Medium quality
Katz JA. et al. 2018, USA, Utility of prenatal MRI in the evaluation and management of fetal ventriculomegaly	Y	Y	Y	Y	Y	U	U	Y	Y	Y	Y	Y	High quality
Frick N. et al. 2015, Austria, The Reliability of Fetal MRI in the Assessment of Brain Malformations	Y	Y	Y	Y	Y	U	U	Y	Y	Y	Y	Y	High quality

Checklist for cohorts studies (1) Is the purpose of the study formulated? (2) Were subjects recruited for the cohort satisfactorily? (3) Was the exposure accurately measured? (4) Was the outcome accurately measured? (5) Have the authors identified and/or taken into account all-important/known possible confounders in the design and analysis of the study? (6) Were any of the people in the cohort followed up? (7) Were the people followed up long enough? (8) What is the result of this study? (9) Do you trust the results? (10) Can the results be transferred to practice? (11) Do the results of this study fit with the results of other available studies? (12) What are the implications of this study for practice? (Answers Yes: Y; No: N; Unclear: U)

From the above assessment of the quality of studies with cohort design, it can be concluded that most of the studies used in this systematic review are in the category of high-quality studies (11 in total), with a smaller number of medium-quality studies (6 in total).

Table 2 determines the importance of prenatal magnetic resonance imaging in making an accurate diagnosis and assessment of CNS anomalies after neurosonographically determined suspicions. Significance was observed through

several cases in which prenatal magnetic resonance imaging confirmed the diagnosis of previously established suspicion on ultrasound. Even more significant is the number of cases in which MRI changed the ultrasound diagnosis and thus established a final, accurate diagnosis. It also ruled out certain cases of CNS anomalies and declared them a normal finding without the presence of anomalies. Also, the total percentage (%) for each group of the cases mentioned above is shown.

Table 2. Significance of prenatal magnetic resonance imaging in making an accurate diagnosis and assessment of central nervous system anomalies after neurosonographically determined suspicion

Main author/ year of publication	MRI confirmed ultrasound diagnosis (n/%)	MRI changed ultrasound diagnosis or added information (n/%)	MRI ruled out ultrasound diagnosis (normal findings) (n/%)	UZ provided additional information for MRI (n/%)
Tanacan A. et al./2020.	59/110 (53,6%)	13/110 (11,8%)	38/110 (34,6%)	0
Mazor MM. et al./2018.	50/78 (64,1%)	9/78 (11,5%)	19/78 (24,4%)	0
Raafat RME. et al./2020.	21/37 (56,8%)	16/37 (43,2%)	ND	3/37 (8,1%)
Turkyilmaz G. et al./2019.	33/36 (91,7%)	3/36 (8,3%)	ND	0
Irwin K. et al./2016.	26/57 (45,6%)	31/57 (54,4%)	6/57 (10,5%)	0
Raafat M. et al./2021.	23/40 (57,5%)	6/40 (15%)	NP	0
Jarre A. et al./2017.	38/78 (48,7%)	12/78 (15,4%)	28/78 (35,9%)	0
Mahmod M. et al./2021.	45/60 (75%)	1/60 (1,6%)	ND	0
Ziaulhaq P. et al./2020.	9/23 (39,1%)	11/23 (47,8%) 2/23 (8,7%)	ND	1/23 (4,4%)
Frick N. et al./2015.	40/56 (71%)	12/56 (21,4%)	4/56 (7,1%)	0
Total percentage (%)	59,8%	20,2%	16,5%	0,8%

(Notes and abbreviations (since several cases from these studies were used in Table 3, the total percentage in this table is below 100%; ND- no data)

Sequence protocols on which the success of MRI detection itself depends and the importance of magnetic resonance imaging in making an accurate and precise diagnosis of CNS anomalies were also analyzed. Table 3 lists the primary data (magnetic field strength, type of MRI device, sequences used, and sequence parameters) relevant to each study used in this review and related to magnetic resonance imaging of the fetal CNS.

Table 3. Technical parameters based on which magnetic resonance imaging was performed

Main author/year of publication	Magnetic field strength/ type of MRI device	Sequence protocol
The ENSO Group/2020.	ND	ND
Tanacan A.et al./2020.	1,5 T Siemens	T2W HASTE (TR/TE 2290/185ms, thickness 3mm); T1 FLASH (TR/TE 140/2,4; FA=70°); DWI (TR/TE 4800/116ms; bmax 600s/mm ²)
Sefidbakht S.et al./2016.	1,5 T Siemens Avanto	T2W HASTE and TRUFI SP (thickness 4-6mm); T1 FLASH
Mazor MM. et al./2018.	1,5 T GE Optima	T2W SSFSE (TR/TE 1298/90ms; matrix 320x224; FOV 24-30cm; thickness/gap 3-4/0mm); spoiled T1 GRE (TR/TE 160/2,3ms; FOV 40cm; thickness/gap 4/0,5mm); DWI (b= 0 and 1000 or 700s/mm ²)
Raafat RME. et al./2020.	1,5 T Philips Achieva XR	T2W SSFSE; SSTSE; spoiled T1 GRE
Turkyilmaz G. et al./2019.	1,5 T GE- Explorer	T2W SSFSE (thickness 2-3mm); T1 WI
Irwin K. et al./2016.	1,5 T Siemens Avanto	T1, T2 (HASTE, FLASH), DWI (thickness 3-5mm)
Linh LT. et al./2021.	1,5 T GE Signa HD	T2W SSFSE in 3 planes; axial T1W and DWI
Raafat M. et al./2021.	1,5 T Philips	T2W B-FFE (TR/TE 3,5/1,7ms; matrix 256x256; FOV 300-400mm; thickness/gap 5/0mm; FA=80°); T2W SSFSE (TR/TE 1500/120ms; matrix 169x256; FOV 200-300mm; thickness/gap 3-4/0,5mm; FA=90°); T1W (TR/TE 120/4ms; matrix 166x256; FOV 300mm; thickness/gap 5/0,5mm; FA=70°)
Jarre A. et al./2017.	1,5 T Siemens Avanto 1,5 T GE Signa Excite	T2W FSE (HASTE/SSFSE) (thickness/gap 3/0,3mm); True Fisp/FIESTA (thickness/gap 4/0,4mm; FOV 260-320mm); EPI DWI (b=600s/mm ²)
Kandula T. et al./2015.	1,5 T Siemens Avanto	T2W HASTE
Mahmod M. et al./2021.	1,5 T Philips	ND
Yilmaz E. et al./2018.	1,5 T Siemens	T2W HASTE (TR/TE 1200/91ms; matrix 192x256; thickness 3mm, FOV 207x100; FA 150°); axial T1 FLASH (TR/TE 199/4ms; matrix 134x256; thickness 4mm; FOV 300x75; FA 70°); sag and cor T1 FLASH in suspected bleeding and parenchymal lesions
Ziaulhaq P. et al./2020.	3T Siemens Skyra	T2W SSFSE; DWI (b=0-600s/mm ²)
Velipaşaoğlu M. et al./2018.	3T GE	SSFSE (CUBE) sequence (ND)
Katz JA. et al./2018.	1,5T and 3T GE	T2W SSFSE sequence in 3 planes (ND)
Frick N. Et al/2015.	1,0T Siemens 1,5T Ingenia Philips 3T Achiva Philips	T2W SSFSE (TR/TE 2100/90ms; thickness 5mm; FOV 330x300mm; matrix 138x256; acquisition time 40s); T1W axial; TRUFI SP-sag; DWI; FLASH; FLAIR (rarely used sequences)

Abbreviations: T (Tesla); DWI (diffusion weighted imaging); W (weighted); HASTE (Half-Fourier Acquired Single-shot Turbo spin Echo); FLASH (fast low angle shot); SSFSE (single shot fast spin-echo); TR/TE (time to repeat/time to echo); TRUFI SP (True FISP); FOV (Field of view); FA (flip angle); GE (General Electric); GRE (gradient echo); SSTSE (single shot turbo spin-echo); B-FFE (Balanced Fast Field Echo); FIESTA (Fast Imaging Employing Steady-state Acquisition); EPI (Echo-planar imaging); WI (weighted imaging); sag (sagittal); cor (coronal); FLAIR (fluid attenuated inversion recovery); ND (no data)

Then, if additional anomalies detected only by magnetic resonance are considered, Table 4 was created for this purpose in which the incidence of fetal CNS anomalies missed on ultrasound imaging and diagnosed on magnetic resonance imaging was analyzed. Relevant data from 12 studies were used for this analysis, which offered the exact number of

cases in which MRI revealed additional anomalies missed on prenatal ultrasound. For easier analysis, in addition to the number of cases of additional anomalies, the table also lists the initial ultrasound suspicions or diagnoses and, most often, additional anomalies detected within each study by magnetic resonance

Table 4. Anomalies of the central nervous system missed on ultrasound and detected by prenatal magnetic resonance imaging

Main author/year of publication	Initial ultrasound suspicion/ diagnosis	Additional anomalies were identified on MRI and missed on ultrasound (n / N /%)	Most common additional anomalies (n)
The ENSO Group/2020.	Isolated mild or moderate VM	30/556; 5,4%	ICH (8); polymicrogyria (6); lissencephaly (4); hypoplasia of CC (2)
Sefidbakht S.et al./2016.	Suspicion of CNS anomalies / the most common indication of isolated VM	18/107; 16,82%	DW variants (3); Chiari II malformation (3); PACC, CACC, aqueductal stenosis (2)
Mazor MM. et al./2018.	Suspicion of corpus callosum anomalies	22/78; 28,2%	Calpocephaly (13); intrahemispheric cysts (4); ventricular asymmetry and gyration disorder (2)
Turkyilmaz G. et al./2019.	Suspicion of corpus callosum anomalies	3/36; 8,1%	PFA (1); cortical malformations (2)
Linh LT et al./2021.	Suspicion of CNS anomalies	8/66; 12,1%	Intracranial hemorrhage (6); vascular malformations (2)
Raafat M. et al./2021.	Suspicion of CNS anomalies	11/40; 27,5%	Meningocele (4); polymicrogyria (2); PACC (2); vermian hypoplasia (2)
Jarre A. et al./2017.	Suspected agenesis of the corpus callosum	28/45; 62,2%	VM (22); cortical malformations (15); PFA (7); midline malformations (3)
Kandula T. et al./2015.	Bilateral or unilateral VM	10/59; 17%	ICH; lesions of the corpus callosum; periventricular anomalies; CSP anomalies (1)
Mahmod M. et al./2021.	Isolated ventriculomegaly	14/60; 23%	CC and CSP lesions (29%); PFA (28%); cortical malformations (21%)
Yilmaz E. et al./2018.	Suspicion of CNS anomalies / the most common indication of VM	22/54; 40%	Subependymal nodules (2); cortical tuber (2)
Velipaşaoğlu M. et al./2018.	The most common indication is isolated ventriculomegaly	12/50; 24%	Posterior fossa defects (36,4%)
Katz JA. et al./2018.	All cases of ventriculomegaly	58/74; 78%	Cortical anomalies; PFA; midline; additional vascular anomalies
Total percentage (%)		19,3%	

Abbreviations: UZ (ultrasound), MRI (magnetic resonance imaging), CNS (central nervous system), VM (ventriculomegaly), ICH (intracranial hemorrhage), CC (corpus callosum), CSP (cavum septum pellucid), PFA (posterior fossa anomalies), DW (Dandy-Walker), CACC/PACC (complete/partial agenesis of corpus callosum)

Finally, Table 5 depicts an analysis of the impact of prenatal magnetic resonance imaging on clinical decision-making and outcomes of central nervous system anomalies. Data from 7 studies were used for this analysis, which provided information on the number of cases of termination and continuation of pregnancy and data on neonatal death and the number of

stillbirths. In several studies, some cases were lost for follow-up. In contrast, in others, postnatal MRI was not available, so only certain studies could compare their data with postnatal MRI data and provide information on the outcome of the anomalies.

Table 5. The impact of prenatal magnetic resonance imaging on clinical decision making and outcomes of central nervous system anomalies

Clinical outcomes	ACCEPTABLE STUDIES						
	Tanacan A. et al./2020.	Turkyilmaz G. et al./2019.	Irwin K. et al./2016.	Raafat M. et al./2021.	Jarre A. et al./2017.	Kandula T. et al./2015.	Ziaulhaq P. et al./2020.
Termination of pregnancy	14/72 12,7%	18/36 50%	11/57 19%	7/40 17,5%	21/30 47,7%	4/59 6,8%	7/23 30,4%
Continuation of pregnancy	ND	17/36 47,2%	46/57 81%	33/40 82,5%	9/30 20,5%	55/59 93,2%	16/23 69,6%
Neonatal death	3/72 2,7%	ND	1/46 2,2%	4/40 10%	ND	3/55 5,5%	ND
Stillborn	2/72 1,8%	1/36 2,8%	2/46 4,3%	2/40 5%	1/9 11%	ND	ND
Characteristics of the study	Termination of pregnancy in 50% of cases of ACC	Normal neurodevelopment in 8 cases and developmental delay expected in the remaining 8 cases	Developmental delay in 14/43 cases; childbirth (33%)	27/40 (67.5%) studies resulted in childbirth	In 8 live births, postnatal MRI confirmed the prenatal diagnosis of ACC	Greater MRI specificity results in additional important information that can help advise parents on the clinical outcome, the likelihood of recurrence	The study did not provide data on postnatal imaging and follow-up of patients

Abbreviations: ND (No data), ACC (agenesis of corpus callosum), MRI (magnetic resonance imaging)

DISCUSSION

In the 10 studies applied in Table 2 and 575 cases, MRI confirmed the ultrasound diagnosis in 59.8% of cases. In contrast, in 20.2% of cases, it changed the diagnosis established on ultrasound, or in 16.5% of cases in which ultrasound established the diagnosis, MRI confirmed the normal finding. Our results are consistent with the results of the study conducted by Jarvis D. and colleagues (32), who in their meta-analysis confirmed the agreement of ultrasound and magnetic resonance imaging in 55% of cases; discrepancy in 23% of cases and 25% of cases in which ultrasound established the diagnosis, MRI confirmed the normal finding. Also, Van Doorn M. and colleagues (33) noted in 65% of cases the agreement of these two modalities; in 26% of cases, MRI provided additional or different pathology, and 12% rejected ultrasound diagnosis. In our study, only 2/10 of the studies, conducted by Raafat RME et al., and Ziaulhaq P. et al. (19,28), provided data in which ultrasound provided additional information to magnetic resonance imaging. These rates were 8.1% (19) and 4.3% (28) and mainly related to facial abnormalities and restriction of intrauterine growth, which can be explained as technological advances in ultrasound and

the skills of the radiologist performing the examination. While Rossi AC. and colleagues (34) in their study recorded only 2% of cases in which ultrasound was more accurate than MRI. Consequently, based on the data from Table 3, it is possible to conclude that a 1.5T MRI device was most often used to record the fetal CNS, while 3T devices were used in our work in only 4/17 studies. As the best protocol based on the data offered by our studies, we can accept the one that contains the first SSFSE (HASTE) T2 weighted sequences in the sagittal, coronal and axial planes, as they are key to reducing fetal movement (thus reducing artifacts). In addition, most studies as additional sequences, and depending on the indications themselves, most often used T1 weighted sequences (FLASH, GRE) in the axial plane, which proved to be the best for detecting bleeding, fat and calcifications or myelin; and DWI sequences in the axial plane which, as an advanced technique, enable the distinction between developmental and destructive pathologies. Based on our results in Table 4, anomalies missed on ultrasound and detected on MRI occurred in 236/1225 cases, totaling 19.3% of additional anomalies. The most common additional anomalies were: intracranial hemorrhage; cortical anomalies, medial anomalies; and PFA. This rate of additional

anomalies in the study conducted by Reda AM. and colleagues (35) was slightly higher, 22.5%. Also, studies conducted by Jarvis D. and colleagues and Rossi AC. and colleagues (32,34) were reported additional information provided by MRI in 15% and 22.1% of cases, respectively. Most authors claim that the risk of finding additional CNS abnormalities in fetuses with isolated ventriculomegaly is high and that it increases with the increasing severity of ventriculomegaly (36,37). This confirms that in 7/12 of the studies used in Table 4, with a significant incidence of associated anomalies, the initial suspicion or diagnosis on ultrasound was precisely ventriculomegaly. This is also supported by the study results conducted by Di Mascio D. and colleagues (37), who reported 3.5% and 22.6% of associated anomalies detected on MRI and missed on ultrasound in fetuses with isolated mild, that is, moderate ventriculomegaly.

The detection of these additional anomalies by MRI indicates its importance in making clinical decisions and enabling parents to make a more conscious decision about their pregnancy. All of our 7 studies from Table 5 were provided information on the number of terminations of pregnancy that occurred in 82/317 cases, accounting for 25.9%. One study that was used did not provide data on the continuation of pregnancy, so based on the remaining studies, the pregnancy was continued in a total of 176 cases. Data on neonatal deaths were not available in the 3 studies used, and 11 cases of neonatal death were recorded in other studies. The number of stillbirths or deaths after birth was reported in 8 cases, as 2 studies did not provide data. Di Mascio D. and colleagues (37) sought to determine whether the detection of associated anomalies by MRI led to a change in prenatal management of pregnancy due to a higher risk of abnormal neurodevelopment outcomes. They proved that 4.6% of fetuses who had an isolated VM on ultrasound and then an additional anomaly on MRI had a significant change in perinatal treatment (mostly termination of pregnancy at the parents' request). Furthermore, in their study Mazor MM. and colleagues (18) state that MRI contributed to a change in management of pregnancy for 28 fetuses (35.9%), of which 25 fetuses (32.1%) are in favor of preserving pregnancy.

CONCLUSION

Ultrasound is the standard way of recording anomalies in the second and third trimesters. Still, MRI using T2W SSFSE sequences in 3 planes, T1W and DWI in the axial plane, is a complementary modality to prenatal ultrasound in making an accurate diagnosis and assessment of CNS anomalies offering a significant percentage of change cases or complete exclusion of previously established ultrasound suspicion. The incidence of additional detected CNS anomalies on magnetic resonance imaging, which were previously missed on ultrasound, indicates the benefit of performing the same in cases when ultrasound examination is unclear or incomplete and when these additional anomalies are far beyond the range and ability of ultrasound to diagnose them. Finally, prenatal MRI with the diagnosis of associated / additional CNS abnormalities may influence clinical decision-making regarding the continuation or termination of pregnancy and, finally, the preparation of family and clinicians for postnatal care depending on the presence or absence of abnormal neurodevelopmental outcomes.

LITERATURE

1. Vegar-Zubović S, Behmen A, Bektesević H, Prevljak S, Džananović A, Bukvić M. et al. Magnetic Resonance Imaging in the Diagnosis of Fetal Pathology. *Acta Inform Med.* 2019;27(1):50-53.
2. Werner H, Gasparetto TD, Daltro P, Gasparetto EL, et Júnior EA. Typical lesions in the fetal nervous system: correlations between fetal magnetic resonance imaging and obstetric ultrasonography findings. *Ultrasonography.* 2018;37(3):261–274.
3. Verburg B, Fink AM, Reidy K, Palma-Dias R. The Contribution of MRI after Fetal Anomalies Have Been Diagnosed by Ultrasound: Correlation with Postnatal Outcome. *Fetal Diagnosis and Therapy* 2015;38(3):186-194.
4. Schneider JF. Case series: Fetal* MR imaging of the brain at 3T. *Clinical fetal imaging. MAGNETOM Flash.* 2011;100-104. [accessed 02.10.2021]. Available from: <http://www.siemens.com/magnetom-world>.
5. Cater SW, Boyd BK, Ghate SV. Abnormalities of the Fetal Central Nervous System: Prenatal US Diagnosis with Postnatal Correlation. *Radiographics.* 2020;40(5):1458-1472.
6. Stamenković J. Poremećaji fetalnog rasta i razvoja: Mogućnosti ultrazvučne dijagnostike u proceni postnatalnog ishoda anomalija centralnog nervnog sistema. *Udruženje za fetalnu i neonatalnu medicinu.* Beograd. 2016;8-13.
7. Novakov-Mikić A, Ljubić A. Razvijanje regionalnog prekograničnog sistema dijagnostičkih centara za prenatalnu dijagnostiku fetalnih malformacija na području Temišvara i Vršca. *Vršac: Opšta bolnica Vršac.* 2014;5-8.
8. Tee LMF, Kan EYL, Cheung JCY, Leung WC. Magnetic resonance imaging of the fetal brain. *Hong Kong Med J.* 2016; 22(3):270–278.
9. Girard N, Chaumoitre K. Prenatal Diagnosis by Fetal Magnetic Resonance Imaging. *Genetic Disorders and the fetus.* 2015;660-680.
10. Reith W, Haussmann A. et Yilmaz U. Fetal Magnetresonanztomographie. *Der Radiologe.* 2018;58(7);668-672.
11. Jokhi RP, Whitby EH. Magnetic resonance imaging of the fetus. *Developmental Medicine and Child Neurology.* 2010;53(1):18-28.
12. Jarvis D.A, Griffiths P.D. Current State of MRI of the Fetal Brain In Utero. *Journal of Magnetic Resonance Imaging.* 2019;49:632–646.
13. Julardžija F, Šehić A, Hasanbegović A, Voloder E, Nikšić M, Merhemić Z. Magnetna rezonanca u ranom otkrivanju anomalija centralnog nervnog sistema. *Radiološke tehnologije.* 2011;4:35-37.

14. National Heart, Lung, and Blood Institute (NHLBI). Study Quality Assessment Tools. [internet]. 2013 [accessed 02.10.2021]. Available at: <https://www.nhlbi.nih.gov/health-topics/study-quality-assessment-tools>
15. The ENSO Working Group. Role of prenatal magnetic resonance imaging in fetuses with isolated mild or moderate ventriculomegaly in the era of neurosonography: international multicenter study. *Ultrasound Obstet Gynecol.* 2020;56(3):340-347.
16. Tanacan A, Ozgen B, Fadiloglu E, Unal C., Oguz K.K., Beksac M.S. Prenatal diagnosis of central nervous system abnormalities: Neurosonography versus fetal magnetic resonance imaging. *Eur J Obstet Gynecol Reprod Biol.* 2020.;250:195-202.
17. Sefidbakht S, Dehghani S, Safari M, Vafaei H, Kasraeian M. Fetal Central Nervous System Anomalies Detected by Magnetic Resonance Imaging: A Two-Year Experience. *Iranian Journal of pediatrics.* 2016; 26 (4):e4589.
18. Mazor MM, Brenner AW, Yosef OB, Hoffmann C, Mazor RD, Mosheva M. et al. Added Value of Fetal MRI in the Evaluation of Fetal Anomalies of the Corpus Callosum: A Retrospective Analysis of 78 Cases. *Ultraschall Med.* 2018;39(5):513-525.
19. Raafat RME, Abdelrahman TM, Hafez MAF. The prevalence and the adding value of fetal MRI imaging in midline cerebral anomalies. *Egyptian Journal of Radiology and Nuclear Medicine.* 2020;51:31.
20. Turkyilmaz G, Sivrikoz TS, Erturk E, Ozcan N, Tatlı B, Karaman B. et al. Utilization of neurosonography for evaluation of the corpus callosum malformations in the era of fetal magnetic resonance imaging. *J Obstet Gynaecol Res.* 2019;45(8):1472-1478.
21. Irwin K, Henry A, Gopikrishna S, Taylor J, Welsh AW. Utility of fetal MRI for workup of fetal central nervous system anomalies in an Australian maternal-fetal medicine cohort. *Aust N Z J Obstet Gynaecol.* 2016;56(3):267-73.
22. Linh LT, Duc NM, Nhung N-TH, My T-TT, Luu DT, Lenh B.V. Detecting Fetal Central Nervous System Anomalies Using Magnetic Resonance Imaging and Ultrasound *Med Arch.* 2021; 75 (1):45-49.
23. Raafat M, Alalfy M, Nagy O, Saraya S. Fetal brain MRI: how it added to ultrasound diagnosis of fetal CNS anomalies-1 year experience. *Egypt J Radiol Nucl Med.* 2021; 85(52).
24. Jarre A, Salvador RL, Fornas GM, Filardi AM. Value of brain MRI when sonography raises suspicion of agenesis of the corpus callosum in fetuses. *Radiologia.* 2017; 59 (3):226-231.
25. Kandula T, Fahey M, Chalmers R, Edwards A, Shekleton P, Teoh M. et al. Isolated ventriculomegaly on prenatal ultrasound: what does fetal MRI add?. *J Med Imaging Radiat Oncol.* 2015; 59(2):154-62.
26. Mahmod M, Ragaee SM, Hamed ST., Abbas A., Mourad MA. The impact of adding fetal MRI to sonographically diagnosed intrauterine ventriculomegaly: a prospective cohort study. *Proc Obstet Gynecol.* 2021;10(2):13.
27. Yilmaz E, Bakir B, Kalelioglu HI, Yuksel A, Has R, Tatli B. et al. Additional Findings from Fetal Magnetic Resonance Imaging for Prenatal Sonographic Diagnosis of Central Nervous System Abnormalities. *Eurasian Journal of Medicine and Investigation EJMI* 2018;2(3):111-117.
28. Ziaulhaq P, Khan NA, Banday S. The comparative study of antenatal magnetic resonance imaging and ultrasound in the evaluation of fetal central nervous system abnormalities. *CHRISMED J Health Res* 2020;7(3):188-192.
29. Velipaşaoğlu M, Şaylısoy S, Öcal E, Tanır H. Assessment of the Additional Value of Fetal Magnetic Resonance Imaging to Prenatal Ultrasound in a Single Institution. *Osmangazi Tıp Dergisi.* 2018;40(2):47-52.
30. Katz JA, Chock VY, Davis AS, Blumenfeld YJ, Hahn JS, Barnes P. Utility of prenatal MRI in the evaluation and management of fetal ventriculomegaly. *Journal of Perinatology.* 2018;38 (11):1444-1452.
31. Frick N, Fazelnia C, Kanzian K, Hitzl W, Fischer T, Forstner R. et al. The Reliability of Fetal MRI in the Assessment of Brain Malformations. *Fetal Diagnosis and Therapy.* 2015; 37(2):93-101.
32. Jarvis D, Mooney C, Cohen J, Papaioannou D, Bradburn M, Sutton A, et al. A systematic review and meta-analysis to determine the contribution of mr imaging to the diagnosis of foetal brain abnormalities In Utero. *European Radiology.* 2016;27 (6):2367-2380.
33. Van Doorn M, Rengerink KO, Newsum EA, Reneman L, Majoie CB, Pajkrt E. Added value of fetal MRI in fetuses with suspected brain abnormalities on neurosonography: a systematic review and meta-analysis, *The Journal of Maternal-Fetal & Neonatal Medicine.* 2015;1-13.
34. Rossi AC, Prefumo F. Additional value of fetal magnetic resonance imaging in the prenatal diagnosis of central nervous system anomalies: a systematic review of the literature. *Ultrasound Obstet Gynecol* 2014;44:388-393.
35. Reda AM, Ali REM, Salem HAA, El-Shafey KE. Added Value of Fetal Magnetic Resonance Imaging in Diagnosis of Central Nervous System Congenital Anomalies in Egyptian Population. *International Journal of Medical Imaging.* 2018;6(4):40-48.
36. Yazbek S, Grant PE. Fetal Brain MRI: Patterned Approach and Review. *Neurographics.* 2015;5(5):181-191
37. Di Mascio D, Sileo FG, Khalil A, Rizzo G, Persico N, Brunelli R. et al. Systematic review and meta-analysis on the role of prenatal magnetic resonance imaging in the era of fetal neurosonography: mild and moderate ventriculomegaly. *Ultrasound in obstetrics and gynecology.* 2018;1-10